



Steep keratometry and central pachymetry after corneal collagen cross-linking procedure in patients with keratoconus

Strma keratometrija i centralna pahimetrija nakon kornealne kolagen *cross-linking* procedure kod bolesnika sa keratokonusom

Mirko Resan^{*†‡}, Miroslav Vukosavljević^{*†‡}, Elisaveta Stanić[‡], Bojan Kovač^{*},
Dragana Ristić^{*†‡}, Maja Petrović[§], Brigitte Pajić-Eggspuehler^{||},
Bojan Pajić^{†||**}

Military Medical Academy, *Eye Clinic, Belgrade, Serbia; University of Defence,
†Faculty of Medicine of the Military Medical Academy, Belgrade, Serbia; ‡Special
Ophthalmic Hospital „Milmedic“ Belgrade, Serbia; Clinical Center of Niš, §Eye Clinic,
Niš, Serbia; ||Eye Clinic ORASIS, Swiss Eye Research Foundation, Reinach AG,
Switzerland; University of Novi Sad, Faculty of Science, ¶Department of Physics, Novi
Sad, Serbia; University Hospitals of Geneva, Department of Clinical Neurosciences,
**Division of Ophthalmology, Geneva, Switzerland

Abstract

Background/Aim. Keratoconus is a disorder of the eye which results in progressive thinning of the cornea. The cross-linking procedure (CXL) is applied in the treatment of initial progredient forms of keratoconus. It is aiming at increasing biomechanical stability of corneal stromal tissue to slow down or stop progressing the ectatic disorder. The aim of the study was to examine the effect of CXL procedure on values of steep keratometry (K2) and central pachymetry (CCT) six months after the intervention in keratoconus-affected patients. **Methods.** Clinical prospective cohort study included 30 eyes of 29 patients suffering from keratoconus. All patients were examined on Allegro-Oculyzer in order to diagnose and follow up keratoconus, thus obtaining corneal topography parameters and parameters important for this study: K2 and CCT, preoperatively and six months postoperatively. The CXL procedure was carried out by following the modified Dresden Protocol. **Results.** K2 mean value was 49.01 ± 3.99 diopter (Dpt) preopera-

tively and 48.06 ± 4.46 Dpt six months postoperatively. K2 decreased six months postoperatively by 0.95 Dpt, proportionally in all patients. Student's paired sample *t* test showed that average decrease of K2 ($\bar{d} = 0.95$ Dpt) was highly statistically significant ($t = 3.381$; $p < 0.01$). CCT mean value was 480.17 ± 36.62 μm preoperatively and 444.37 ± 45.01 μm six months postoperatively. CCT decreased six months postoperatively by 35.8 μm , proportionally in all patients. Student's paired sample *t* test showed that average decrease of CCT ($\bar{d} = 35.8$ μm) was highly statistically important ($t = 6.40$; $p < 0.001$). **Conclusion.** Application of CXL procedure in the treatment of keratoconus with confirmed progression highly reduces steep keratometry and central pachymetry six months postoperatively. By steep keratometry reducing effect the CXL procedure is efficient in the treatment of keratoconus, especially its initial stages.

Key words: keratoconus; corneal topography; corneal pachymetry; collagen.

Apstrakt

Uvod/Cilj. Keratokonus je oboljenje oka koje uzrokuje progresivno tanjenje kornee. “Cross-linking” (CXL) procedura primenjuje se u lečenju početnih progredijentnih formi keratokonusa. Ona ima za cilj da pojača biomehaničku stabilnost tkiva strome rožnjače čime usporava, odnosno zaustavlja progresiju ektatičnog procesa. Cilj rada bio je ispitivanje uticaja CXL procedure na vrednosti strme keratometrije (K2) i centralne pahimetrije (CCT) šest meseci posle iz-

vedene intervencije kod bolesnika obolelih od keratokonusa. **Metode.** U kliničku prospektivnu kohortnu studiju bilo je uključeno 30 očiju (29 bolesnika) obolelih od keratokonusa. U cilju dijagnostike keratokonusa i daljeg praćenja, svakom bolesniku obavljen je pregled na Allegro Oculyzer-u kojim su dobijeni parametri kornealne topografije i za studiju bitni parametri: K2 i CCT, preoperativno i šest meseci postoperativno. CXL procedura izvedena je po modifikovanom Dresdenskom protokolu. **Rezultati.** Srednja vrednost K2 preoperativno iznosila je $49,01 \pm 3,99$ dioptrija (Dpt), dok je

šest meseci postoperativno bila $48,06 \pm 4,46$ Dpt. Prosečno kod svih bolesnika šest meseci postoperativno došlo je do smanjenja vrednosti K2 za 0,95 Dpt. Student-ov *t*-test vezanog uzorka pokazao je da za prosečno smanjenje vrednosti K2, $d = 0,95$ Dpt, postoji visoko statistički značajna razlika ($t = 3,381$; $p < 0,01$). Srednja vrednost CCT preoperativno bila je $480,17 \pm 36,62$ μm , dok je 6 meseci postoperativno iznoila $444,37 \pm 45,01$ μm . Prosečno, kod svih pacijenata 6 meseci postoperativno došlo je do smanjenja vrednosti CCT za 35,8 μm . Student-ov *t* test vezanog uzorka pokazao je da za prosečno smanjenje vrednosti CCT od $d = 35,8$ μm po-

stoji vrlo visoka statistička značajnost ($t = 6,40$; $p < 0,001$). **Zaključak.** CXL procedura u lečenju keratokonusa sa dokazanom progresijom, dovodi do značajnog smanjenja strme keratometrije i značajnog smanjenja centralne pahimetrije šest meseci postoperativno. Efektom smanjenja strme keratometrije CXL procedura je efikasna u lečenju keratokonusa, posebno njegovih početnih stadijuma.

Ključne reči:
keratokonus; kornealna topografija; kornea, pahimetrija; kolagen.

Introduction

Keratoconus is a non-inflammatory ectatic corneal disease which is characterized by biomechanical weakness of stromal tissue causing progressive corneal thinning, resulting in irregular conical corneal shape. Keratoconus is featured with central and paracentral stromal thinning, apical protrusion and irregular astigmatism. This disease is mostly bilateral, with 1 : 2,000 prevalence, and it affects young working people with deterioration of visual acuity caused by irregular astigmatism. Etiology of the disease is unclear, and heredity exists only in 10% of cases¹. There are different therapeutic options. Rigid contact lenses or implantation of intrastromal corneal ring segments can be applied in initial stages of the disease. Keratoplasty is performed in terminal stages due to extreme corneal steepening and scarring to achieve visual rehabilitation².

Corneal collagen cross-linking (CXL) procedure with the use of riboflavin and ultraviolet-A (UVA) irradiation is a new surgical method in keratoconus treatment. Structural abnormalities in stromal collagen are the cause of deformity and thinning of cornea suffering from keratoconus. CXL procedure directly strikes these abnormalities by using UVA irradiation and photosensitizer riboflavin, thus creating new covalent bonds (cross-links) between collagen fibers aiming at improving rigidity and biomechanical stability of cornea. This procedure helps stopping further progression of the ectatic process³, clinically manifested with decreasing of steep keratometry (K2) and therefore improving of visual acuity.

This study is aiming at examining the impact of CXL procedure on values of K2 and central pachymetry (CCT) in patients with keratoconus 6 months after the intervention.

Methods

A clinical, prospective cohort study was carried out. It included 30 eyes of 29 patients (19 males, 10 females) suffering from keratoconus. In one patient both eyes were operated on. The average age of patients was 32 (32.40 ± 12.24) years.

All patients were examined on Allegro-Oculyzer (Wavelight, Germany) in order to diagnose keratoconus, thus also providing corneal topography parameters: K2 and CCT. Complete ophthalmologic examination of all patients was performed (automatic refractometry, best corrected

visual acuity, ocular tonometry, eye fundus observation). After diagnosing keratoconus and confirming the disease progression (increased K2 values in comparison to previous examinations), respecting a condition that central corneal thickness should not be below 400 μm after corneal epithelium removal in order to avoid endothelial cell damage during the intervention, all eyes diseased underwent the CXL procedure.

The CXL procedure was carried out by following the modified Dresden Protocol⁴. In a sterile environment of the operating room, after applying a topical anesthetic (Benoxi[®] Unimed Pharma eye drops – sol. oxybuprocaine 4 mg/mL), corneal epithelium was removed within a 9 mm wide circular zone with hokey knife, rotating brush or excimer laser. A 0.1% riboflavin solution (10 mg riboflavin-5-phosphate in 10 mL dextran-T-500 20% solution) was applied topically every 2 minutes during 30 minutes. Central pachymetry was checked with Reichert iPac handheld pachymeter to be over 400 μm . Cornea was UVA irradiated (365 nm, 3.0 mW/cm²) with UV lamp (UV-X 1000 IROC Innocross AG, Swiss) during the course of a 30 minute exposure. Riboflavin solution was applied to the cornea every 2 minutes during irradiation. At the end of the procedure, a combination of topical steroid and antibiotic drops (sol. tobramycin 0.3% + sol. dexamethason 0.1%; Tobradex[®], Alcon) was administered, then followed by a bandage contact lens application which was removed the fifth postoperative day. Every patient was dispensing Tobradex[®] drops three times a day and Hylocomod[®] drops (sol. sodium hyaluronate 0.1%, Ursapharm) eight to ten times a day during a month after the intervention.

All the patients were examined on Allegro-Oculyzer six months after the intervention in order to provide corneal topography parameters: K2 and CCT. Complete ophthalmologic checkup of all patients was also performed.

Statistical data were processed with methods of descriptive and inferential statistics: mean, standard deviation, maximum and minimum range, mode and median for descriptive statistics, and Student *t*-test for analytical statistics.

Results

Parameters important for the study are presented in Table 1. K2 mean value was 49.01 ± 3.99 diopters (Dpt) preoperatively and 48.06 ± 4.46 Dpt six months postoperatively. K2 therefore decreased six months postoperatively by 0.95

Dpt proportionally in all patients. Student's paired sample *t*-test showed that average decrease of K2 ($d = 0.95$ Dpt) was highly statistically significant ($t = 3.38$; $p < 0.01$). CCT mean value was 480.17 ± 36.62 μm preoperatively, and 444.37 ± 45.01 μm six months postoperatively. CCT therefore decreased six months postoperatively by 35.8 μm , proportionally in all patients. Student's paired sample *t* test showed that average decrease of CCT ($d = 35.8$ μm) was highly statistically significant ($t = 6.40$; $p < 0.001$).

Figure 1 shows corneal topography parameters of patient number 15 before the CXL procedure, while Figure 2 shows corneal topography parameters of the same patient six

months after the intervention. It can be observed that patient's K2 decreased by 1 Dpt and CCT decreased by 48 μm six months after the CXL procedure.

In our research there were not any particular complications in the course of the six month follow up. Yet there were a couple of things to consider when talking about early postoperative period. Firstly, there was a prolonged re-epithelization in the patient whose epithelium was removed with rotational brush. Also, if we are talking about the other two methods of epithelium removal, in all the patients re-epithelization was as expected and with mild discomfort.

Table 1

Parameters important for the treatment of keratoconus

Patient No	Gender	Age (years)	Epithelium removal method			Steep K (Dpt)		CCT (μm)	
			rotational brush	hokey knife	excimer laser	Preop.	6 months postop.	Preop.	6 months postop.
1	m	29	+			54.1	54.9	456	401
2	f	21		+		45.7	45.3	469	427
3	m	31			+	60.4	59.8	471	423
4	m	23		+		42.9	40.9	495	467
5	m	19		+		49.1	48.3	489	434
6	m	19		+		53.7	55.8	497	438
7	m	41		+		50.9	49.2	545	532
8	f	30		+		50.8	48.0	472	400
9	f	28			+	49.8	48.7	478	447
10	f	26		+		54.8	52.8	470	458
11r	f	29			+	51.5	50.2	490	442
12l	f	29			+	50.6	51.7	496	488
13	f	22		+		51.6	49.4	450	417
14	m	42		+		45.4	44.6	524	478
15	m	22			+	49.3	48.3	492	444
16	m	27		+		42.7	42.8	464	445
17	m	37		+		47.7	45.8	462	396
18	m	39		+		44.5	43.5	518	478
19	m	56		+		46.0	45.7	467	447
20	m	16		+		43.5	42.2	441	415
21	m	19		+		51.6	53.9	427	411
22	m	19		+		44.8	44.5	457	446
23	m	21		+		44.3	42.8	541	493
24	f	47		+		47.1	46.9	455	431
25	m	63		+		47.7	47.1	464	495
26	m	39		+		49.1	48.3	552	537
27	f	47		+		51.0	51.6	412	408
28	f	48		+		51.3	47.0	447	305
29	m	47		+		50.8	49.4	446	440
30	f	36		+		47.6	42.5	558	488
mean \pm SD		32.40 ± 12.24				49.01 ± 3.99	48.06 ± 4.46	480.17 ± 36.62	444.37 ± 45.01

m – male; f – female; Steep K – steep keratometry; CCT – central pachymetry.

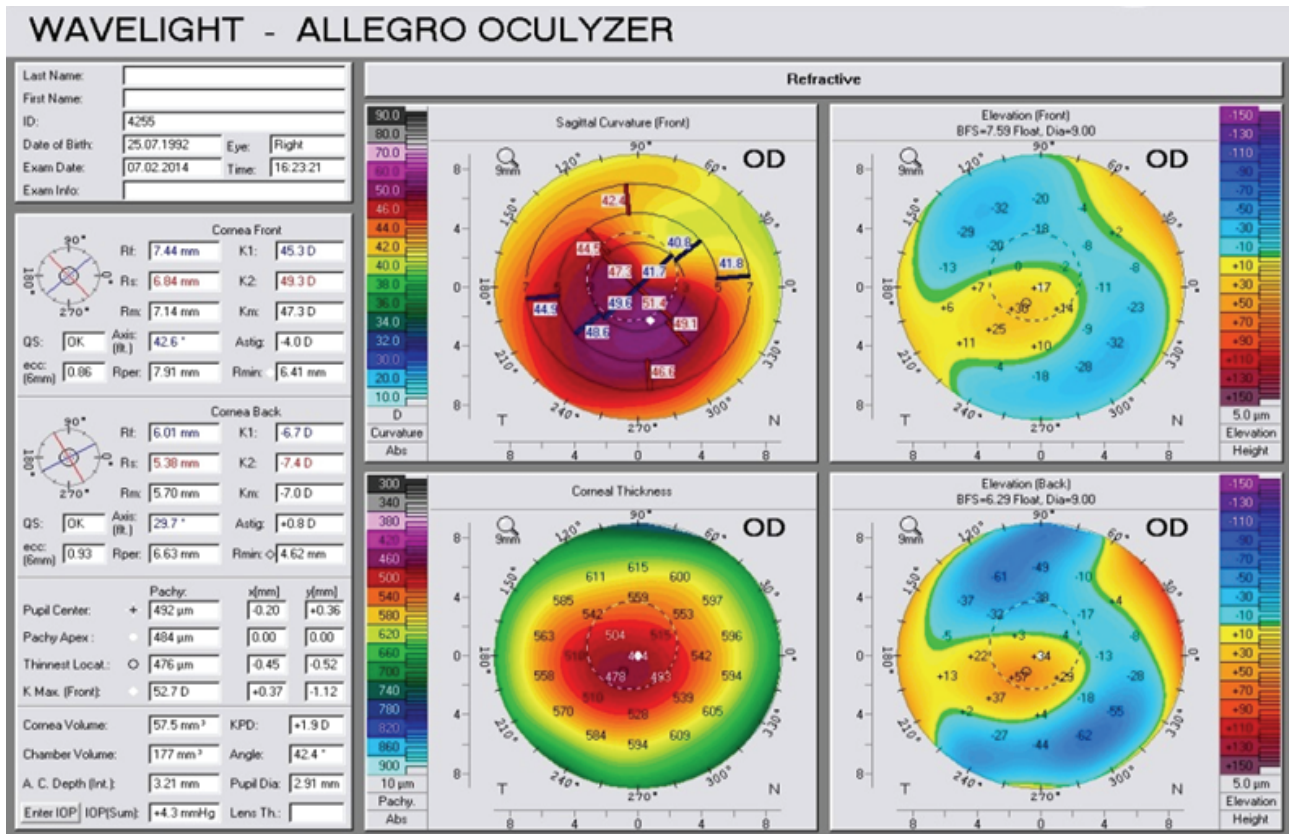


Fig. 1 – Corneal topography parameters before cross-linking (CXL) procedure (patient number 15).

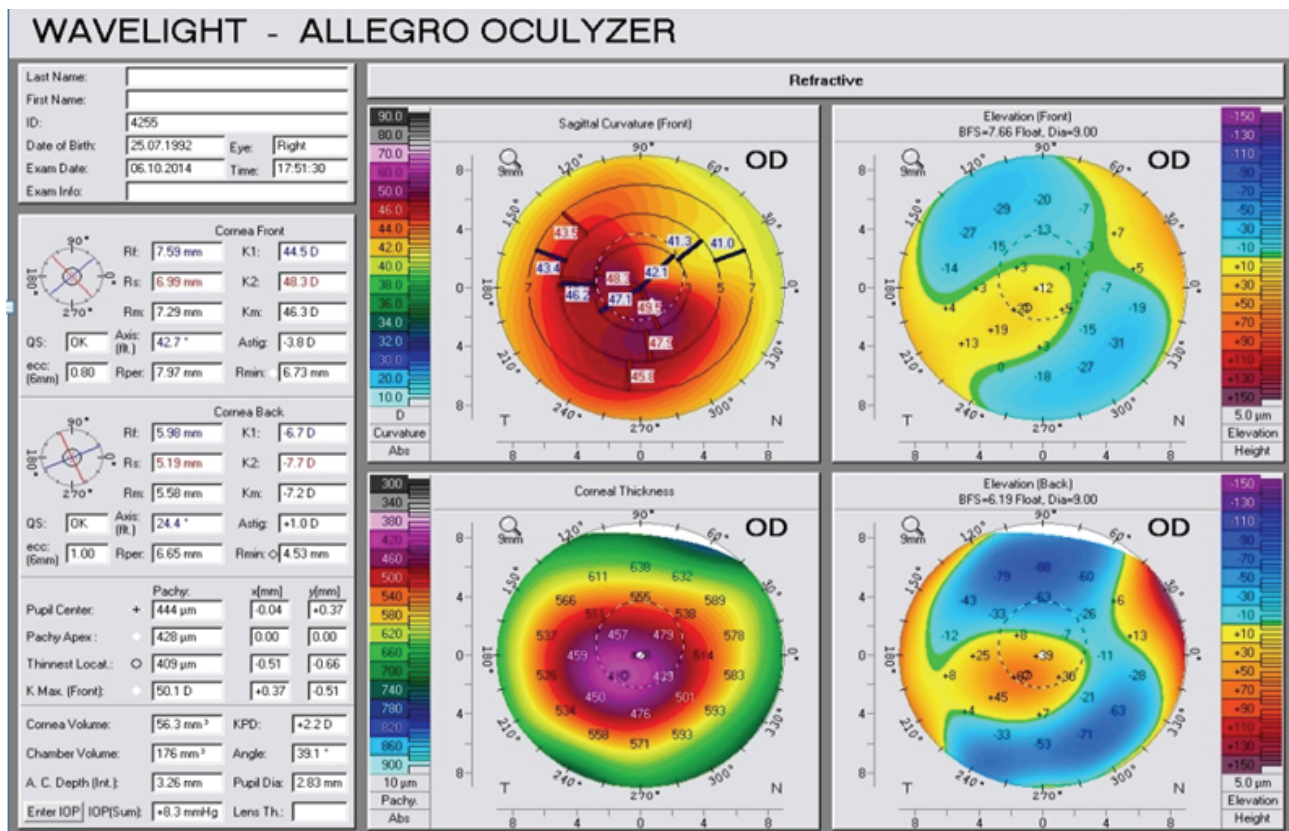


Fig. 2 – Corneal topography parameters 6 months after cross-linking (CXL) procedure (patient number 15).

Discussion

Our study showed that six months after the CXL procedure there was an average 0.95 Dpt reduction of K2 value. The present study also showed that six months after the CXL procedure there was an average 35.8 μm reduction of CCT value.

A study of Hersh et al.⁵ showed that during the first month after the CXL procedure there was a rise of steep keratometry, while six months past the intervention there was a decrease of steep keratometry for 0.8 Dpt (from 52.9 Dpt preoperatively to 52.1 Dpt 6 months postoperatively). Koller et al.⁶ indicated in their study, which included 151 eyes operated by the CXL procedure, that one year after the intervention there was a corneal flattening (change in maximum K value) for more than 1 Dpt in 37.7% of eyes and for more than 2 Dpt in 13% of eyes.

The study of Greenstein et al.⁷ showed that there was corneal thinning within the first three months after the CXL procedure, while after six months preoperative pachymetric values resumed. In their study mean value of corneal thickness at the apex was 458.2 μm preoperatively, 437.8 μm one month postoperatively, 428.3 μm three months postoperatively and 446.3 μm six months postoperatively. The study of Sharma et al.⁸ showed that central corneal thickness decreased by mean 22.7 μm six months after the CXL procedure.

The aim of the CXL procedure is to slow down or stop progressing the ectatic disorder on a keratoconus-affected cornea. This is clinically demonstrated by reducing K2 value

and therefore reducing astigmatism and improving visual acuity.

Our study confirmed that by reduction in the value of K2, the CXL procedure is effective to stop or slow down further progression of the ectatic process. Our study also showed that the CXL procedure leads to a reduction in the value of CCT. Exact causes of corneal thinning are still unknown. They could be anatomic and structural changes in corneal collagen fibrils such as compression of collagen fibrils⁹, and keratocyte apoptosis¹⁰.

There were no complications in our study during the six month follow up. However, it is stated in the literature that the most serious complication of the CXL procedure (in 2.9% of patients) is endothelial loss leading to persistent corneal edema^{11, 12}. We did not have this case because we followed the principle to leave central pachymetry greater than 400 μm after removing epithelium, which we checked with handheld pachymeter. As possible complications after the CXL procedure, other authors state sterile infiltrates in 7.6% of eyes and central stromal scars in 2.8%¹³.

Conclusion

Application of the CXL procedure in the treatment of keratoconus with confirmed progression highly reduces steep keratometry and central pachymetry six months postoperatively. By steep keratometry reducing effect the CXL procedure is efficient in the treatment of keratoconus, especially its initial stages.

R E F E R E N C E S

1. *Feder RS, Kshtetry P.* Noninflammatory ectatic disorders. In: *Krachmer JH, Mannis MJ, Holland EJ*, editors. *Cornea*. Philadelphia: Elsevier-Mosby; 2005. p. 955–74.
2. *Beshvani IM, O'Donnell C, Radhakrishnan H.* Biomechanical properties of corneal tissue after ultraviolet-A-riboflavin crosslinking. *J Cataract Refract Surg* 2013; 39(3): 451–62.
3. *Raiskup F, Spoerl E.* Corneal crosslinking with riboflavin and ultraviolet A. I. Principles. *Ocul Surf* 2013; 11(2): 65–74.
4. *Wollensak G, Spoerl E, Seiler T.* Riboflavin/ultraviolet-a-induced collagen crosslinking for the treatment of keratoconus. *Am J Ophthalmol* 2003; 135(5): 620–7.
5. *Hersh PS, Greenstein SA, Fry KL.* Corneal collagen crosslinking for keratoconus and corneal ectasia: One-year results. *J Cataract Refract Surg* 2011; 37(1): 149–60.
6. *Koller T, Pajić B, Vinciguerra P, Seiler T.* Flattening of the cornea after collagen crosslinking for keratoconus. *J Cataract Refract Surg* 2011; 37(8): 1488–92.
7. *Greenstein SA, Shah VP, Fry KL, Hersh PS.* Corneal thickness changes after corneal collagen crosslinking for keratoconus and corneal ectasia: One-year results. *J Cataract Refract Surg* 2011; 37(4): 691–700.
8. *Sharma N, Suri K, Sebra SV, Titiyal JS, Sinha R, Tandon R, et al.* Collagen cross-linking in keratoconus in Asian eyes: Visual, refractive and confocal microscopy outcomes in a prospective randomized controlled trial. *Int Ophthalmol* 2015; 35(6): 827–32.
9. *Seiler T, Hafezi F.* Corneal cross-linking-induced stromal demarcation line. *Cornea* 2006; 25(9): 1057–9.
10. *Wollensak G, Spoerl E, Wilsch M, Seiler T.* Keratocyte apoptosis after corneal collagen cross-linking using riboflavin/UVA treatment. *Cornea* 2004; 23(1): 43–9.
11. *Sharma A, Nottage JM, Mirchia K, Sharma R, Mohan K, Nirankari VS.* Persistent corneal edema after collagen cross-linking for keratoconus. *Am J Ophthalmol* 2012; 154(6): 922–926.e1.
12. *Lange C, Böhringer D, Reinhard T.* Corneal endothelial loss after crosslinking with riboflavin and ultraviolet-A. *Graefes Arch Clin Exp Ophthalmol* 2012; 250(11): 1689–91.
13. *Koller T, Mrochen M, Seiler T.* Complication and failure rates after corneal crosslinking. *J Cataract Refract Surg* 2009; 35(8): 1358–62.

Received on May 2, 2016.

Revised on December 11, 2017.

Accepted on December 11, 2017.

Online First December, 2017.